

Cultural Competence Case Presentation Child Abuse/Coin Rubbing (Cultural, Race)

Matt Leonard MD, Bryant Cameron Webb, Stephanie Chao and Marcus L. Martin MD

Case Scenario/History

A young Asian mother brings her 5 year-old daughter to the ED for evaluation of a fever and cough. The mother smiles sheepishly as you introduce yourself and maintains little eye contact. A family friend, who has accompanied the mother and daughter and who speaks very little English, says that 'she is sick for long time'. When you ask if they have taken any medicine for the fever, the friend replies 'yes, pills'. Further questioning does not reveal the identify or quantity of pills.

a. Review of Symptoms

Fever and cough. No NVD.

b. Past Medical History

Immunizations UTD as reported by friend.

c. Family History

Non-contributory.

d. Social History

Lives at home with Mom, Dad, grandparents and two younger brothers. Family arrived from Vietnam 'a while ago'. She does not attend school. Medications and allergies unknown.

e. Physical Exam

Temp: VS: T – 100.1 F, HR – 90, BP – 100/70, R – 20, O₂Sat 98% RA

General: Anxious, alert, thin female in NAD

ENT: PERRL, mild rhinorrhea, nasal mucosa edematous, moist oral mucosa. TMs clear bilaterally, oropharynx erythematous without exudates, non-enlarged tonsils

Neck: Supple, without rigidity, mild lymphadenopathy

Cardiovascular: RRR, no murmur, rubs or gallops

Lungs: CTA bilaterally, no wheezing or crackles

Abdomen: Soft, non-tender, nondistended, BS present throughout

Extremities: No clubbing, cyanosis or edema

Skin: Multiple purpuric lesions on back in angular, descending pattern bilaterally encompassing entire back. No other rashes, petechiae, or bruising on extremities

Neuro: Alert and awake, CN II-XII intact, DTRs 2+ throughout

Questions for discussion

1. What barriers to effective communication exist in this circumstance?

Obviously, the lack of understanding of the English language will limit the utility of a history and physical exam. Also, certain cultural practices limit the effectiveness of a clinical interaction. Asian culture emphasizes the avoidance of eye contact and politeness as a sign of compliance to medical treatment(1). A friendly tone, appropriate eye contact and positive hand gestures establish verbal and non-verbal trust and rapport in such cases.

2. How would you go about obtaining a thorough history in this case?

Immediately, the need for interpretive services is evident. The widespread use of family members and friends as interpreters compromises both the accuracy of the patient's reported history and the explanation of medical language. The duration of fever, characteristics of cough, previous medical interventions, sick contacts, and any other constitutional symptoms are important points in the history.

3. How do you interpret your physical exam findings?

This is a febrile, healthy appearing female child who appears to be in no acute respiratory distress. She is saturating well on room air and her HEENT exam does not favor a bacterial cause for her symptoms and she displays no meningeal symptoms. Her chest and lung exam also is non-concerning for pneumonia. The lesions on her back are concerning for either intentional burns/rubs from child abuse or cultural practices such as coining, common in the Asian culture.

4. What is your differential diagnosis at this point?

Coining, Child Abuse, Idiopathic Thrombocytopenic Purpura, Hemophilia, Vitamin K deficiency, Henoch-Scholein Purpura, Mongolian Spots(2)

5. What would be your next appropriate step to take?

Unfortunately, many ED physicians jump directly to child protective services in such cases. The proper procedure in this case would be to obtain a full historical account of the markings from both the parent and the child, separately if needed. In cases of suspected child abuse, the location, time, and mechanism of injury need to be documented(2).

6. Are there any other diagnostic tests you would consider at this time?

A CBC and basic metabolic panel could possibly reveal any deficiencies that could be immediately correctable. If you suspected a bleeding diathesis, you could order PT/PTT, platelet count, and INR. The yield on these tests in an otherwise healthy child is low. A possible explanation is allergic rhinitis complicated by viral illness. However, the possibility of immunodeficiency exists and follow-up with an immunologist would be appropriate.

7. *Could anything have been done differently to facilitate this encounter?*

Acknowledging cultural differences up front and asking patients for their opinion about what has caused this illness and how it is affecting them are suggested strategies for dealing with significant cultural mismatches between physician and patient(3). Many patients will not volunteer that they have sought alternative medical help for fear of offending a Western doctor, or embarrassment(1).

8. *What sections of the case incorporate the 6 ACGME areas of core competence?*

- a. **Patient care** – appropriate work-up to include the differential of coining, bleeding disorders and child abuse
- b. **Knowledge** – demonstrates cross-cultural clinical skills by recognizing the use of coining in the Asian population in the United States
- c. **Interpersonal & Communication Skills** – generates effective information exchange between physician, patient and families by utilization of interpreter services. Friendly tone, appropriate eye contact and positive hand gestures establishing verbal and non-verbal trust between physician and patient
- d. **Professionalism** – provide sensitive and ethical care to diverse populations

Case Outcome

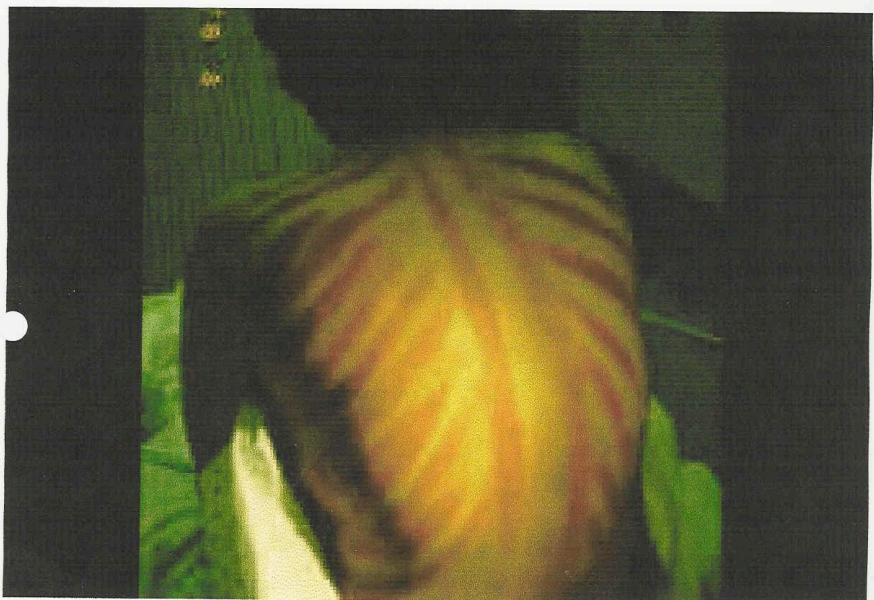
With the aid of a trained interpreter, you are able to discern that the family arrived in the country 18 months ago and has visited a traditional Asian healer in their community who has practiced coining on the girl. In general, there is little danger involved in cultural practices such as **cao gio**, known as coining. There are rare case reports of minor and major burns associated with individuals catching fire during coining(4). She has been sick on and off for the past year with upper respiratory symptoms and has had multiple visits to the ED for similar presenting complaints. Each time, she has been evaluated and felt to have upper respiratory infections and allergies. Otherwise, she has been meeting all of her developmental goals and seems to be quite happy in her new country.

The girl and her mother are discharged from the ED with a follow-up appointment in the pediatric allergy and immunology clinic. She is advised to rest, drink lots of fluids, and take Children's Tylenol for fever analgesia. She is evaluated in the allergy clinic and does well on a low-dose, non-sedating anti-histamine.

Ethnic populations comprised over 31% of the United States population in 2003(3). The majority of the Asian population in the US is located in California and the West Coast. ED physicians and primary care doctors, especially in this area of the country, must recognize the cultural differences between their world and that of their patients in order to avoid the legal and emotional conflicts involved in bringing false accusations of child abuse. Every year, nearly 3 million suspected cases of child abuse are reported to the CPS(4). Luckily, many doctors are aware of practices such as coining, where hot coins and warm oil are rubbed on the backs of the chronically ill to release the 'bad wind'(5). Along with the recognition of different cultural practices, physicians must be aware of the difficulties faced by those patients who do not speak English. Non-English speakers are more likely to be less satisfied with their care, less willing to come to the ED for

emergency care, and many have more health problems than their English-speaking counterparts(3). As a medical community, we must acknowledge these truths and work to account for linguistic barriers, using properly-trained interpreters and dedicating resources for our growing ethnic population.

Example of Coin Rubbing



References

1. Moy J, McKinley-Grant L, Sanchez M. Cultural Aspects in the Treatment of Patients with Skin Disease, *Dermatologic Clinics*, October 2003, 21(4).
2. Christian C. Assessment and evaluation of the physically abused child. *Clinics in Family Practice*, March 2003, 5(1).
3. Rodriguez M. Cultural and linguistic competence: improving quality in family violence health care interventions. *Clinics in Family Practice*, March 2003, 5(1).
4. Amshel C, Caruso D. Vietnamese 'coining': a burn case report and literature review. *Journal of Burn Care and Rehabilitation*, April 2000, 21(2):112-4.
5. Marx: Rosen's Emergency Medicine: Concepts and Clinical Practice, Cultural competence: a tool for enhancing ED care, 2002, 5th edition, 2719-2722.